



DOI: 10.1111/ajo.13304

## ORIGINAL ARTICLE

# Long-term durability of uterine artery embolisation for treatment of symptomatic adenomyosis

Jolande Ma<sup>1,2</sup> , Bevan Brown<sup>2,3</sup> and Eisen Liang<sup>2,3</sup> 

<sup>1</sup>Sydney Medical School, University of Sydney, New South Wales, Australia

<sup>2</sup>Sydney Adventist Hospital Clinical School, University of Sydney, New South Wales, Australia

<sup>3</sup>Sydney Fibroid Clinic, New South Wales, Australia

*Correspondence:* Dr Jolande Ma, Sydney Interventional Radiology, SAN Clinic, Sydney Adventist Hospital, 185 Fox Valley Road, Wahroonga, NSW 2076, Australia. Email: joma9540@uni.sydney.edu.au

*Conflicts of Interest:* The authors report no conflicts of interest.

Received: 31 July 2020;  
Accepted: 7 December 2020

**Background:** Failing conservative therapies, uterine artery embolisation (UAE) has been proposed as a uterine-sparing option for treatment of symptomatic adenomyosis. UAE appears effective at short-term; however long-term durability is less well established.

**Aims:** To evaluate the long-term clinical efficacy of UAE for treatment of adenomyosis.

**Materials and Methods:** One hundred and four women with initial clinical success following UAE for adenomyosis (results previously published) were further followed with a two-part online survey. Part one inquired about menopause, symptom recurrence, need for further intervention and overall satisfaction. Part two comprised the Uterine Fibroid Symptom and health-related Quality of Life (UFS-QOL) questionnaire. Maintenance of clinical success was defined as remaining 'happy' or 'very happy' with overall outcome, no recurrence of symptoms, or need for further intervention.

**Results:** Of those women with initial success, 91/104 (88%) participated in this long-term study at mean 52 months following UAE. Maintenance of clinical success was demonstrated in 82/91 (90%) women. For the remaining 9/91 (10%) women, mean time to failure was 31 months. There were 53/91 (58%) women who reached menopause at mean age of 51.5 years, occurring at mean 30 months post-UAE. UFS-QOL demonstrated significant decrease in symptom severity from 58.9 to 20.0 ( $P < 0.001$ ); and significant increase in QOL from 40.3 to 86.3 ( $P < 0.001$ ).

**Conclusions:** Long-term durability of UAE for treatment of adenomyosis was demonstrated, with cumulative success rate of 80% at mean 52 months. UAE did not appear to bring forward menopause. UAE should be considered as an alternative to hysterectomy to treat adenomyosis.

## INTRODUCTION

Adenomyosis is a benign condition characterised by ectopic endometrial invasion of the underlying myometrium, resulting in hyperplasia and hypertrophy of this muscular layer of the uterus.<sup>1-3</sup> Clinically, adenomyosis may manifest as debilitating heavy

menstrual bleeding (HMB), dysmenorrhoea, symptoms related to uterine enlargement, chronic pelvic pain and dyspareunia.<sup>4,5</sup>

The prevalence of adenomyosis is not well established. Reported figures vary from 0.8%, identified based on database diagnostic coding<sup>6</sup>, to 70%, based on histology of hysterectomy specimens.<sup>1,2</sup> In many cases, adenomyosis overlaps with other

This is an open access article under the terms of the Creative Commons Attribution-NonCommercial-NoDerivs License, which permits use and distribution in any medium, provided the original work is properly cited, the use is non-commercial and no modifications or adaptations are made.

© 2021 The Authors. *Australian and New Zealand Journal of Obstetrics and Gynaecology* published by John Wiley & Sons Australia, Ltd on behalf of Royal Australian and New Zealand College of Obstetricians and Gynaecologists.

gynaecological conditions including fibroids and endometriosis.<sup>1,2,7</sup> The greatest symptomatic burden is seen in women aged 40–50 years.<sup>8</sup>

Conservative treatment options for adenomyosis, aimed at relieving HMB and pain, include non-steroidal anti-inflammatory drugs, tranexamic acid, oral contraceptive pills, levonorgestrel-releasing intrauterine system (LNG-IUS) and short-term use of gonadotropin-releasing hormone (GnRH) agonists.<sup>3,9</sup> Failing conservative therapies, many women are advised to undergo a hysterectomy, which is deemed the only definitive treatment for adenomyosis.<sup>10</sup>

Uterine artery embolisation (UAE) has been proposed as a less invasive alternative to hysterectomy to treat adenomyosis.<sup>5,9,11</sup> UAE is an angiographic procedure whereby an embolic agent is injected into uterine arteries to induce ischaemic infarction of adenomyotic foci.<sup>12,13</sup> The efficacy of UAE for treatment of adenomyosis has been established in the short-term,<sup>5,14–16</sup> but mid- to long-term durability is less clear. While some studies demonstrated high rates of symptom recurrence, with only 45–57% women remaining symptom free at 2–3 years,<sup>10,17</sup> others reported maintenance of clinical success in 70–76% at 3–5 years.<sup>12,13,18,19</sup> The aim of the present study is to evaluate the long-term clinical efficacy of UAE for treatment of adenomyosis to address this discrepancy.

## MATERIALS AND METHODS

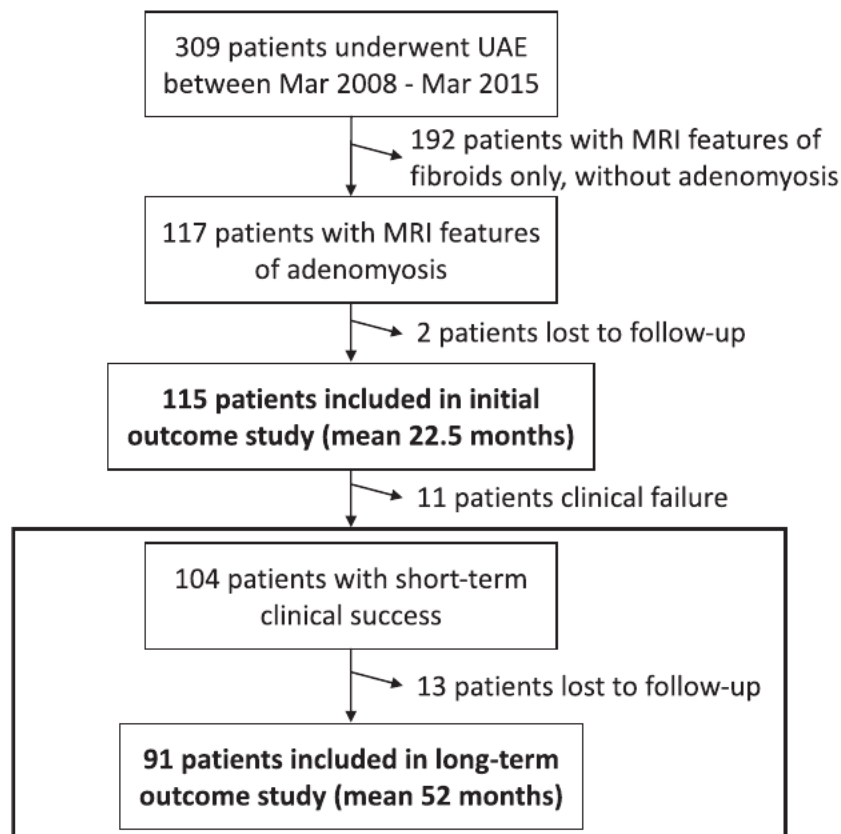
### Study design

This study is a long-term follow-up of our previously published cohort study evaluating short-term outcomes of UAE in 115 women with adenomyosis.<sup>20</sup> The follow-up period for the initial study was a mean of 22.5 months (median 18, range 6–84 months) and clinical success was achieved in 104/115 (90%) women, including two women requiring a repeat UAE. The 104 women who achieved initial success formed the cohort for this long-term outcome study (Fig. 1).

Women were contacted by SMS, email or phone and invited to participate in the study on a voluntary basis. For those who consented to participate, unique links to a two-part secure on-line survey were sent via SMS or email. Women who had already reached menopause at the time of initial short-term study were not contacted.

### Study measures

The first part of the survey was a questionnaire inquiring about menopause, recurrent symptoms of adenomyosis and need for



**FIGURE 1** Study population. The study population for this long-term study was derived from a previously evaluated cohort of women who demonstrated initial clinical success at 22.5 months, following uterine artery embolisation (UAE) for treatment of adenomyosis. Short-term outcomes have previously been published.<sup>20</sup>

further intervention in case of recurrent symptoms. Women were asked if they had entered menopause and if so, when it occurred and whether they were unhappy about it. They were asked to rate their periods, currently or just before they entered menopause, as either: (1) lighter than normal; (2) back to normal; (3) still heavy; or (4) heavier than before UAE. Women with dysmenorrhoea at baseline were asked to rate their pain as either: (1) gone; (2) much better; (3) slight improvement; (4) same; or (5) worse than before UAE. Pain was further quantified using a visual analogue scale (VAS). Women were asked to rate their overall satisfaction with the procedure as: (1) very happy; (2) happy; (3) not sure; (4) not happy; or (5) very unhappy. Finally, women were asked about the need for further intervention for ongoing symptoms.

The second part of the survey comprised the Uterine Fibroid Symptom and health-related Quality of Life (UFS-QOL) questionnaire which provides two scores, the health-related quality of life score (HRQOL) and symptom severity score. Although the UFS-QOL was developed as an objective measure of the impact of fibroids, it has also been used to evaluate adenomyosis.<sup>12,18,21</sup> Symptoms of fibroids and adenomyosis are similar and the two conditions often coexist.<sup>20</sup> HRQOL score > 80 and symptom

severity score < 20 may be considered asymptomatic.<sup>22</sup> The UFS-QOL was implemented in our clinical follow-up from mid-2009.

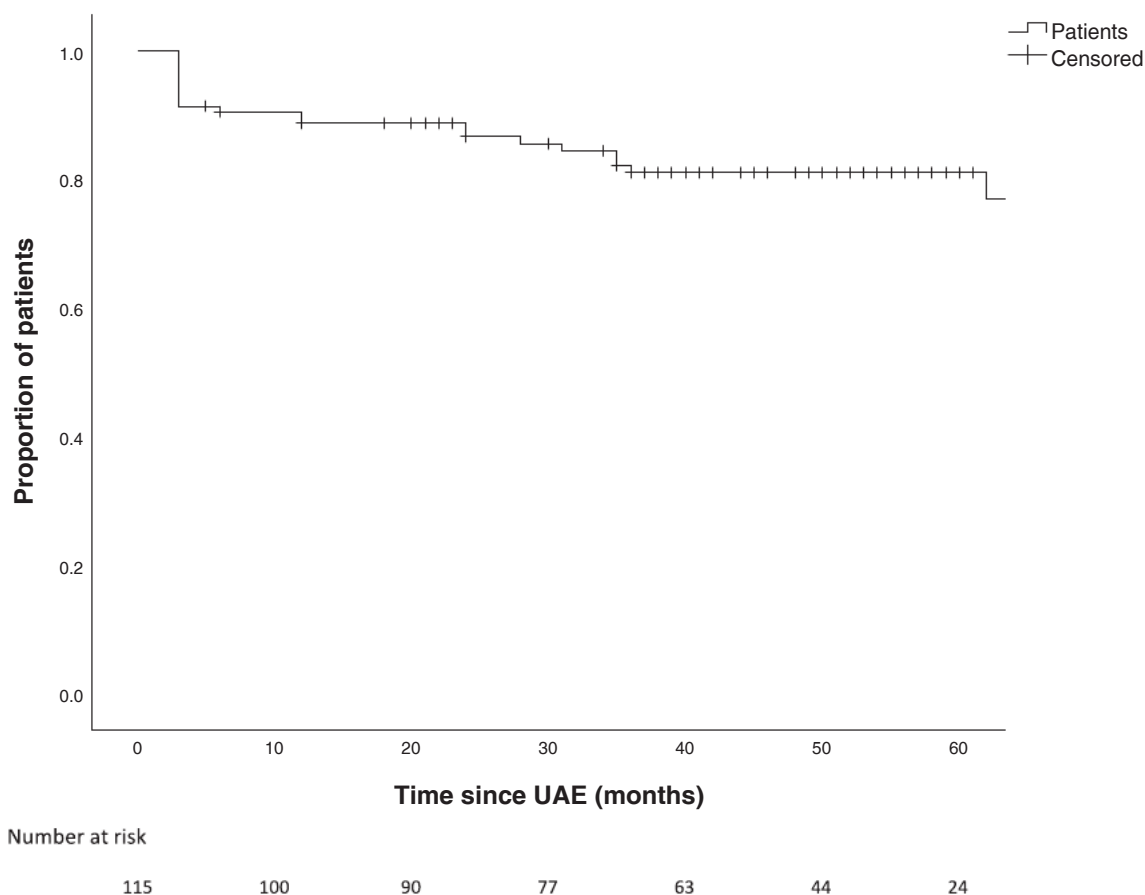
Long-term clinical success was defined as patient satisfaction rated as either 'happy' or 'very happy' with overall outcome, no recurrence of symptoms and no need for further interventions.

For those women who indicated undesirable outcomes, telephone contact was made to clarify the nature of clinical failure, and further clinical assessment and treatment offered.

### Statistical analysis

Data analysis was completed in SPSS statistical software version 24 (IBM SPSS, Armonk, NY, USA). Summary descriptive statistics were used to evaluate demographic characteristics; and longitudinal comparisons of pain, symptom severity and HRQOL were analysed using paired Student's *t*-test. KaplanMeier survival analysis was performed to determine the proportion of patients demonstrating maintenance of clinical success following UAE, over time. A *P*-value < 0.05 was considered statistically significant.

Post-hoc sensitivity analyses were completed in SPSS to determine the effect of outliers, missing data and varying definitions



**FIGURE 2** KaplanMeier analysis demonstrating maintenance of clinical success over time. This chart illustrates the proportion of women with adenomyosis treated with uterine artery embolisation (UAE) who remained satisfied with overall outcome, with no recurrence of symptoms or need for secondary intervention, as a function of time since UAE. Included in this analysis is the cumulative short- and long-term outcome following UAE for treatment of adenomyosis (*n* = 115)

of clinical success on outcomes. The alternative criteria for clinical success included: UFS-QOL, avoidance of hysterectomy, self-reported satisfaction and self-reported symptoms. Multiple imputation was used in the analysis of missing data.

This study was approved by the Adventist HealthCare Limited Human Research Ethics Committee (HREC 2016-040) and informed consent was obtained from each participant.

## RESULTS

Of the 104 women with initial success following UAE from our previous short-term outcome study, five women declined participation and eight women were unable to be contacted. Thus, 91/104 (88%) women were included in this long-term outcome study. Mean follow-up duration was 52 months from UAE (median 50, range 5–117 months). Patient demographics are included in Table S1.

In this long-term study, 82/91 (90%) women remained 'happy' or 'very happy' with the overall long-term outcome, reported no recurrence of symptoms, or need for further interventions. Maintenance of clinical success over time is illustrated in Figure 2.

Of those with pain before UAE, 6/74 (8%) women developed recurrence of dysmenorrhoea. Of those with HMB before UAE, 8/91 (9%) women developed recurrent HMB. Long-term symptomatic control was achieved in the remaining patients. A significant decrease in pain and symptom severity score and a significant increase in HRQOL compared to baseline was observed at long-term (Table 1).

The criteria for maintenance of clinical success was not met in 9/91 (10%) women (Table 2). Mean time to failure for these cases was 31 months (median 31, range 12–62 months) following UAE. Reasons for failure include recurrence of HMB in 3/9 (33%) women, dysmenorrhoea in 1/9 (11%) woman, and both HMB and dysmenorrhoea in 5/9 (56%) women. Recurrence of dysmenorrhoea in one woman prompted laparoscopy which subsequently revealed co-existent severe endometriosis. Total re-intervention rate was 4/91 (4%). Re-intervention involved

LNG-IUS in 2/91 (2%), laparoscopy in 1/91 (1%) and hysterectomy in 1/91 (1%).

By long-term follow-up, 53/91 (58%) women had reached menopause, at mean age of 51.5 years (95% CI 50.6–52.4) and at mean period of 30 months (median 26, range -12–100 months) after UAE. None of the women who reached menopause experienced recurrence of symptoms of adenomyosis prior to the onset of menopause. Of those who developed menopause, only one patient was unhappy about the onset of menopause due to hot flushes.

Sensitivity analyses showed results remained robust with respect to outliers and missing data; however, varying rates of clinical success (ranging from 82% to 93%) were observed with the application of alternative criteria for clinical success.

## DISCUSSION

Our previously published initial outcomes at mean follow-up of 22.5 months demonstrated short-term success in 104/115 (90%) women following UAE for treatment of adenomyosis. For those women who achieved initial success, this long-term follow-up study demonstrated durability of UAE in 82/91 (90%) women at mean follow-up of 52 months. Additional failures at long-term, secondary to symptom recurrence, occurred in 9/91 (10%) women, at mean 31 months post-UAE.

Excluding those lost to follow-up, the combined short and long-term success rates of UAE for treatment of adenomyosis are estimated to be 82/102 (80%), with cumulative failure rate of 20/102 (20%) at 52 months.

The total re-intervention rate from short- and long-term is 13/102 (13%). This is comprised of three cases of repeat UAE (3%) from short-term: one further hysterectomy in addition to the six hysterectomies reported at short-term, giving a total hysterectomy rate of 7/102 (7%); two cases of LNG-IUS (2%) and one case of laparoscopy (1%) reported at long-term.

Our findings support the long-term durability of UAE for treatment of adenomyosis. This is consistent with several studies

**TABLE 1** Long-term outcomes at mean 52 months following UAE for treatment of adenomyosis ( $n = 91$ )

Outcome	Baseline	Long-term	P-value
Dysmenorrhoea			
VAS pain score, mean	6.6 (median 8, range 0–10)	1.6 (median 1, range 0–7)	$P < 0.001$
Reported long-term control, $n$	–	68/74 (92%)	–
HMB			
Reported long-term control, $n$	–	83/91 (91%)	–
UFS-QOL†			
HRQOL score, mean	40.3 (median 39, range 2–90)	86.3 (median 94, range 22–100)	$P < 0.001$
Symptom severity score, mean	58.9 (median 56, range 15–100)	20.0 (median 13, range 0–75)	$P < 0.001$

HMB, heavy menstrual bleeding; HRQOL, health-related quality of life; UFS-QOL, Uterine Fibroid Symptom and health-related Quality of Life; UAE, uterine artery embolisation; VAS, visual analogue scale.

†UFS-QOL completed by  $n = 75$ .

**TABLE 2** Additional cases of clinical failure at long-term (mean 52 months) following UAE for treatment of adenomyosis (n = 9)

Case	Age at UAE	Type of adenomyosis	Pathology	JZ thickness (mm)	Uterine volume (cm <sup>3</sup> )	Time to failure (months)	Reason for failure	Further intervention
1	40	Diffuse	Pure adenomyosis	14	173	12	Both HMB and dysmenorrhoea	Hysterectomy
2	35	Mixed	Pure adenomyosis	18	378	62	Both HMB and dysmenorrhoea	-
3†	30	Diffuse	Pure adenomyosis	13	88	28	Both HMB and dysmenorrhoea	-
4	42	Focal	Pure adenomyosis	14	145	24	Both HMB and dysmenorrhoea	Tranexamic acid
5	48	Diffuse	Pure adenomyosis	22	111	12	Both HMB and dysmenorrhoea	-
6	44	Diffuse	Pure adenomyosis	16	173	35	HMB	LNG-IUS
7	43	Diffuse	Adenomyosis with symptomatic fibroids	19	192	35	HMB	-
8	37	Focal	Adenomyosis with symptomatic fibroids	18	135	31	HMB	LNG-IUS
9	37	Diffuse	Pure adenomyosis	15	173	36	Dysmenorrhoea	Laparoscopic resection of severe endometriosis
Mean ± SD	40 ± 5			17 ± 3	174 ± 83	31 ± 15		

HMB, heavy menstrual bleeding; JZ, junctional zone; LNG-IUS, levonorgestrel intrauterine system; UAE, uterine artery embolisation.

Initial failures at short-term (mean 22.5 months) have previously been published.

†Case 3 became unintentionally pregnant three months post-UAE. The pregnancy was complicated with hypertension, gestational diabetes requiring insulin, cervical incompetence, premature rupture of membrane and labour at 33 weeks requiring caesarean section. The infant was on the 83rd centile for weight at birth and 30th centile for height and weight at two years, without developmental issues or dysmorphic features.

including Nijenhuis et al. (2015), which followed 29 women and demonstrated resolution of symptoms in 76% and preservation of uterus in 97% at 37 months.<sup>12</sup> Similarly, Froeling et al. (2012) reported symptomatic control in 29/40 (72.5%) women at 40 months<sup>18</sup> and Smeets et al. (2012) demonstrated symptomatic improvement in 29/40 (72.5%) at 65 months.<sup>19</sup> Zhou et al. (2016) demonstrated improvement in dysmenorrhoea in 107/152 (70.4%) and HMB in 117/170 (68.8%) at 60 months, but recurrence of at least one symptom in 92/195 (47.2%).<sup>13</sup> The observed significant increase in HRQOL and decrease in symptom severity are consistent with other studies utilising the UFS-QOL questionnaire.<sup>12,18,19</sup>

Other long-term studies of UAE for treatment of adenomyosis show less favourable outcomes. Kim et al. (2007) included 54 women with pure adenomyosis and reported a success rate of 57.4% at 58.8 months.<sup>23</sup> Similarly, a clinical success rate of 56% in nine women at 24 months was reported in Pelage et al. (2005).<sup>17</sup> Further evidence of deterioration of symptomatic relief was observed in Bratby and Walker (2009) with reported clinical success rate of 45.5% in 11 patients at 36 months.<sup>10</sup>

Possible reasons for the discrepancy in long-term outcome may be due to the acceptance of near stasis of the uterine artery as the end point for embolisation in Pelage et al. (2005), whereas other studies required complete stasis to be achieved. No methodological discrepancies accounting for failure could be identified in Bratby and Walker (2009); however, they only included 11 participants.<sup>10</sup> Kim et al. (2007) studied pure adenomyosis, whereas most other studies allowed for the co-existence of fibroids in the study population.<sup>23</sup>

Two systematic reviews with meta-analyses reported short- (<12 months) and long-term (>12 months) outcomes following UAE for adenomyosis. Popovic et al. (2011) included 511 patients from 15 studies, with rates of symptomatic relief of 64.9% for pure adenomyosis at median 40.6 months and 82.4% for adenomyosis with fibroids at median 34.2 months.<sup>7</sup> Analysis of 30 studies in de Brujin et al. (2017) included 1049 patients and demonstrated rates of symptomatic improvement of 74% for pure adenomyosis at mean 36 months and 85.4% for adenomyosis with fibroids at mean 34.9 months.<sup>24</sup> While there is considerable overlap in the studies included in these meta-analyses, there is substantial evidence for durability of UAE for treatment of adenomyosis at mid- to long-term. This is consistent with our findings. The meta-analyses also noted that those with adenomyosis with fibroids had better outcomes following UAE compared to those with pure adenomyosis. While this was not directly examined in our study, we note seven of the nine long-term clinical failures had pure adenomyosis.

The application of UAE for treatment of adenomyosis remains novel in comparison to its use in the treatment of fibroids. Whereas several randomised controlled trials and a Cochrane review have demonstrated no difference in patient satisfaction with UAE compared to surgery for treatment of fibroids, this level of evidence is lacking for adenomyosis.<sup>25</sup> The ongoing QUESTA trial seeks to address this by directly comparing UAE to hysterectomy for treatment of adenomyosis.<sup>26</sup>

By long-term follow-up, 58% of women reached menopause, which occurred at mean age of 51.5 years (95% CI 50.6–52.4). This is consistent with the natural age and distribution of menopause in Australia, which is reported to occur at mean age of 51.3 years (95% CI 49.8–52.8).<sup>27</sup> UAE did not appear to bring forward the age of menopause. None of these women experienced recurrence of symptoms before menopause and were therefore considered a clinical success. The mean time from UAE to menopause in these women was 30 months. For those who had not yet reached menopause, the mean time to failure was 31 months. Women treated with UAE closer to their age of menopause might be less likely to experience symptom recurrence after UAE. As better techniques for predicting the timing of menopause become available, such data might be useful in predicting the likely success of an individual woman's UAE procedure. While we acknowledge the potential for menopause to bias results, we emphasise the aim of UAE as an alternative to extirpative surgery, which was previously the only treatment option for adenomyosis failing conservative management. Onset of menopause without requiring a hysterectomy, regardless of timing, will have fulfilled the purpose of UAE.

A major strength of this study is the long duration of follow-up, as there is a paucity of studies beyond short-term of 12–24 months. Our study is among the larger cohorts reported, with a high percentage of patients included in long-term follow-up. Analysis of time to failure adds to our understanding of the durability of UAE for treatment of adenomyosis over time. Similarly, analysis of the onset of menopause in our cohort offers important insights into the effect of UAE on menopause. The use of the UFS-QOL is another strength of the study, allowing for an objective measure of clinical success.

The present study has several limitations. Being a single centre and single operator study, the outcomes may not be generalisable to larger centres with multiple operators. Recall bias may limit the accuracy of responses from women who had already reached menopause at time of long-term follow-up. Menopause was not explicitly defined in the questionnaire, therefore there may be variability in reported onset of menopause between women. Methodological flaws are acknowledged in the unbalanced scale measuring dysmenorrhoea, which may skew results. Finally, our study did not directly address the outcomes of pure adenomyosis compared to adenomyosis with fibroids. Further research into factors that predict clinical outcome are required to improve patient selection.

Sensitivity analyses determined clinical success rate to vary based on how it was defined, highlighting the need to scrutinise criteria for clinical success when comparing studies and to consider all study outcomes. This may account for our higher success rate compared to the existing literature. Alternatively, a higher success rate may reflect our study being a single centre and single operator study, allowing for more consistent patient selection, embolisation technique and embolisation end point.

Previously, failure of conservative therapy for treatment of adenomyosis necessitated hysterectomy for management of



debilitating symptoms. Hysterectomy remains a major surgical procedure requiring general anaesthesia, with inherent surgical risks and longer-term side effects.<sup>7</sup> By contrast, UAE is less invasive and allows preservation of the uterus as is desired by many women.<sup>7,16,24</sup>

This long-term study has confirmed that UAE is a durable, definitive treatment for adenomyosis in 80% of women. Hysterectomies were avoided in 93% of women. UAE did not bring forward menopause. UAE should be offered to women in whom conservative management for adenomyosis has failed, as a less invasive alternative to hysterectomy.

## ACKNOWLEDGEMENTS

We acknowledge the efforts of Patrick McMaster in data collection.

## REFERENCES

- Englander MJ. Uterine artery embolization for the treatment of adenomyosis. *Semin Intervent Radiol* 2008; **25**(4): 387–393.
- Hong SC, Khoo CK. An update on adenomyosis uteri. *Gynecol Minim Invasive Ther* 2016; **5**(3): 132–133.
- Struble J, Reid S, Bedaiwy MA. Adenomyosis: a clinical review of a challenging gynecologic condition. *J Minim Invasive Gynecol* 2016; **23**(2): 164–185.
- Garcia L, Isaacson K. Adenomyosis: review of the literature. *J Minim Invasive Gynecol* 2011; **18**: 428–437.
- Siskin GP, Tublin ME, Stainken BF et al. Uterine artery embolization for the treatment of adenomyosis: clinical response and evaluation with MR imaging. *AJR Am J Roentgenol* 2001; **177**: 297–302.
- Yu O, Schulze-Rath R, Grafton J et al. Adenomyosis incidence, prevalence and treatment: United States population-based study 2006–2015. *Am J Obstet Gynecol* 2020; **15**: 15.
- Popovic M, Puchner S, Berzaczy D et al. Uterine artery embolization for the treatment of adenomyosis: a review. *J Vasc Interv Radiol* 2011; **22**(7): 901–909.
- Lohle PNM, Higue D, Herbreteau D. Uterine artery embolisation in women with symptomatic adenomyosis. *Presse Medicale* 2019; **48**: 435–439.
- Levgur M. Therapeutic options for adenomyosis: a review. *Arch Gynecol Obstet* 2007; **276**: 1–15.
- Bratby MJ, Walker WJ. Uterine artery embolisation for symptomatic adenomyosis—Mid-term results. *Eur J Radiol* 2009; **70**: 128–132.
- Alvi FA, Glaser LM, Chaudhari A et al. New paradigms in the conservative surgical and interventional management of adenomyosis. *Curr Opin Obstet Gynecol* 2017; **29**(4): 240–248.
- Nijenhuis RJ, Smeets AJ, Morpurgo M et al. Uterine artery embolisation for symptomatic adenomyosis with polyzene F-coated hydrogel microspheres: three-year clinical follow-up using UFS-QoL questionnaire. *Cardiovasc Intervent Radiol* 2015; **38**: 65–71.
- Zhou J, He L, Liu P et al. Outcomes in adenomyosis treated with uterine artery embolization are associated with lesion vascularity: a long-term follow-up study of 252 cases. *PLoS One* 2016; **11**(11): e0165610.
- Kim MD, Won JW, Lee DY et al. Uterine artery embolization for adenomyosis without fibroids. *Clin Radiol* 2004; **59**(6): 520–526.
- Lohle PN, De Vries J, Klazen CA et al. Uterine artery embolization for symptomatic adenomyosis with or without uterine leiomyomas with the use of calibrated tris-acryl gelatin microspheres: midterm clinical and MR imaging follow-up. *J Vasc Interv Radiol* 2007; **18**(7): 835–841.
- Wang S, Meng X, Dong Y. The evaluation of uterine artery embolization as a nonsurgical treatment option for adenomyosis. *Int J Gynaecol Obstet* 2016; **133**: 202–205.
- Pelage JP, Jacob D, Fazel A et al. Midterm results of uterine artery embolization for symptomatic adenomyosis: initial experience. *Radiology* 2005; **234**(3): 948–953.
- Froeling V, Scheurig-Muenkler C, Hamm B et al. Uterine artery embolization to treat uterine adenomyosis with or without uterine leiomyomata: Results of symptom control and health-related quality of life 40 months after treatment. *Cardiovasc Intervent Radiol* 2012; **35**(3): 523–529.
- Smeets AJ, Nijenhuis RJ, Boekkooi PF et al. Long-term follow-up of uterine artery embolization for symptomatic adenomyosis. *Cardiovasc Intervent Radiol* 2012; **35**(4): 815–819.
- Liang E, Brown B, Rachinsky M. A clinical audit on the efficacy and safety of uterine artery embolisation for symptomatic adenomyosis: results in 117 women. *Aust N Z J Obstet Gynaecol* 2018; **58**: 454–459.
- Spies JB, Coyne K, Guaou Guaou N et al. The UFS-QOL, a new disease-specific symptom and health-related quality of life questionnaire for leiomyomata. *Obstet Gynecol* 2002; **99**: 290–300.
- de Bruijn AM, Smink M, Hehenkamp WJK et al. Uterine artery embolization for symptomatic adenomyosis: 7-year clinical follow-up using UFS-QoL questionnaire. *Cardiovasc Intervent Radiol* 2017; **40**(9): 1344–1350.
- Kim MD, Kim S, Kim NK et al. Long-term results of uterine artery embolization for symptomatic adenomyosis. *Am J Roentgenol* 2007; **188**: 176–181.
- de Bruijn AM, Smink M, Lohle PNM et al. Uterine artery embolization for the treatment of adenomyosis: a systematic review and meta-analysis. *J Vasc Interv Radiol* 2017; **28**(12): 1629–1642.e1.
- Gupta JK, Sinha A, Lumsden MA, Hickey M. Uterine artery embolization for symptomatic uterine fibroids. *Cochrane Database of Syst Rev* 2014; **12**: CD005073.
- de Bruijn AM, Lohle PN, Huirne JA et al. Uterine artery embolization versus hysterectomy in the treatment of symptomatic adenomyosis: protocol for the randomized QUESTA trial. *JMIR Res Protoc* 2018; **7**(3): e47.
- Davis SR, Lambrinoudaki I, Lumsden M et al. Menopause. *Nature Rev Dis Primers* 2015; **1**: 15004.

## SUPPORTING INFORMATION

Additional supporting information may be found online in the Supporting Information section at the end of the article.

**Table S1.** Demographic and baseline parameters.